



**PATIENT**

Bella Spangler

**SPECIES**

Canine

**BREED**

Australian Cattle Dog  
Mix

**SEX**

Female Spayed

**AGE**

7 years

**WEIGHT**

73.6lbs

**INTERPRETED BY**

Maggie Machen Lamy,  
DVM, DACVIM  
(Cardiology)

**IMAGING PERFORMED BY**

Jack Reese

**HOSPITAL NAME**

Willow Run Veterinary  
Clinic

**REFERRING VET**

Dr. Pendergast

**INVOICE**

47640

**DATE**

4/22/26

**PRESENTING CLINICAL SIGNS**

History: Several week history of labored breathing - most notable when lying down, at rest. Seemed intermittent, but more frequently noted recently. Gagging/vomiting without production. On a grain-free diet. RR 48/min with increased BV sounds in all quadrants. Mild hypoalbuminemia. Elevated BNP: 10,000.

CXR report: cardiomegaly. There is a marked diffuse alveolar pattern with mild bronchial component noted and peribronchial cuffing. Two faint fissure lines observed within R lung on VD. Few small osteomas within caudal lung fields.

-ECG: showed sinus rhythm.

**ECHOCARDIOGRAM FINDINGS**

2D, m-mode, color flow and doppler imaging is available. Severe left ventricular dilation with diminished systolic function. Decreased LV wall thickness with increased sphericity. Severe left atrial enlargement. The mitral valve appears normal in form and function, with no obvious prolapse into the left atrial lumen. Mild central mitral regurgitation secondary to annular stretch. Moderate right atrial and ventricular dilation. Mild tricuspid regurgitation. The aortic valve is normal in morphology and mobility. Normal LVOT velocity. No aortic insufficiency. Normal RVOT velocity. Normal pulmonic valve with trace pulmonic insufficiency seen. No pericardial or pleural effusion noted. No obvious cardiac tumors.

**CARDIAC CHART**

CANINE CARDIAC PARAMETERS	MR VMAX (m/s)	TR VMAX (m/s)	LA/AO (Boon method)	LA/AO (Heart Base; Swe)	FS (%)	EF (%)	EPSS (cm)
<b>NORMAL PARAMETER</b>	4.5-5.5	<2.7	1.3	<1.6	28-40	40-100	<0.6
<b>PATIENT</b>	NM	NM	NM	2.2	12	20	NM
CANINE CARDIAC PARAMETERS	HR (BPM)	AV VMAX (m/s)	PV MAX (m/s)	BODY WEIGHT (kg)	LA 2D short axis Base view (cm)	LVIDd Avg; 2D and m-mode short axis (cm)	LVIDs Avg; 2D and m-mode short axis (cm)
<b>NORMAL PARAMETER</b>	50-100	0.7-1.7	0.7-1.6	BELOW	BELOW	BELOW	BELOW
<b>PATIENT</b>	NM	0.9	0.8	33.4	4.6	6.9	6.0
<b>*Normal chamber parameters expressed as a mean value (SD)</b>				3	1.27 (5.3)	2.46 (2.46)	1.36 (5.5)
<b>BODY WEIGHT DEPENDENT PARAMETERS</b>				5	1.40 (4.5)	2.74 (5.2)	1.60 (4.7)
<i>*Note: All measurements based upon multi-modal images and methods. An average value is reported.</i>				10	1.50 (3.8)	3.27 (3.5)	2.06 (3.1)
				15	1.83 (2.0)	3.71 (2.4)	2.43 (2.1)
				20	2.02 (1.9)	4.14 (2.2)	2.80 (2.0)
				25	2.18 (2.4)	4.48 (2.9)	3.10 (2.5)
				30	2.33 (3.3)	4.83 (3.9)	3.39 (3.4)
				35	2.48 (4.3)	5.17 (5.0)	3.69 (4.5)
				40	2.62 (5.2)	5.48 (6.1)	3.96 (5.4)
				50	2.88 (7.1)	6.07 (8.3)	4.46 (7.4)

Adapted from June Boon, Veterinary Echocardiography, 1998  
Rishniw M and Hollis NE, J Vet Intern Med 2000; 14:429-435  
Hansson et al, Vet Rad and Ultrasound 2002  
Bonagura et al. Echocardiography: principles of interpretation, Vet Clin North Am 15:1177, 1995



## PATIENT

Bella Spangler

## SPECIES

Canine

## BREED

Australian Cattle Dog  
Mix

## SEX

Female Spayed

## AGE

7 years

## WEIGHT

73.6lbs

## INTERPRETED BY

Maggie Machen Lamy,  
DVM, DACVIM  
(Cardiology)

## IMAGING PERFORMED BY

Jack Reese

## HOSPITAL NAME

Willow Run Veterinary  
Clinic

## REFERRING VET

Dr. Pendergast

## INVOICE

47640

## DATE

4/22/26

## INTERPRETATION OF THE FINDINGS & FURTHER RECOMMENDATIONS

Unfortunately, this patient has significant cardiomyopathy and systolic dysfunction. There is dilation and volume overload of both the left and right heart resulting in insufficiency of the mitral and tricuspid valves. The severity of dysfunction and pump failure is great, and the patient is at high risk for decompensating into congestive failure. Patient will always be at risk for right and/or left-sided CHF, development of arrhythmias/syncope and/or sudden death going forward.

Development of the DCM-phenotype can be primary in nature (ie genetic DCM as is seen in Dobermans) or develop secondary to a variety of issues such as a non-traditional diet, myocarditis, hypothyroidism, chronic tachycardia, or infiltrative disease such as lymphoma. While primary disease is certainly possible, consider testing for underlying causes. At a minimum, a diet history and thyroid status should be obtained. Other possible steps include evaluating a cardiac troponin level (cTnI; assess for myocarditis) and/or taurine level (assess for a malabsorption issue). Finally, further systemic evaluation for underlying issues such as neoplasia may also be reasonable if suspicion is elevated (abdominal ultrasound, etc.).

Regardless of cause, the patient is reportedly experiencing clinical and radiographic evidence of CHF, and immediate institution of full cardiac supportive medications is recommended as below. Cases of systolic failure are at high risk for tachyarrhythmias (such as VT or rapid AF) and sudden death, and this should be expressed to the owner. Activity restriction is advised, and a baseline ECG recommended.

Prognosis is guarded to poor at this stage in the disease process, with an average survival time of <6 months.

Elective anesthesia is not advised due to high risk for complications.

Omega fatty acid supplementation and mild salt restriction may be of some long-term benefit. Monitor for development of a cough, worsening labored breathing, abdominal distention, exercise intolerance or collapse episodes in the future. Monitoring of sleeping breathing rates at home is recommended to assess response to medications and recurrence of CHF in the future.

## PLAN:

Baseline BP recommended. Initiate aldosterone antagonist Spironolactone 1-2mg/kg PO q12h. Institute furosemide 1-2mg/kg PO q12h. Institute Pimobendan 0.3mg/kg PO q12h. Institute taurine supplement 1000mg PO q12h. Consider diet history/thyroid status and further screening as discussed.

Monitor a renal panel and blood pressure in 1-2 weeks to ensure tolerance of medications, then every 3-4 months lifelong. If BP > 130mmHg and the patient is doing well at home, institute an ACEI 0.5mg/kg PO q12h.

A recheck echocardiogram is recommended in 6 months to screen for progression, sooner if clinical issues arise in the interim.



## PATIENT

Bella Spangler

## SPECIES

Canine

## BREED

Australian Cattle Dog  
Mix

## SEX

Female Spayed

## AGE

7 years

## WEIGHT

73.6lbs

## INTERPRETED BY

Maggie Machen Lamy,  
DVM, DACVIM  
(Cardiology)

## IMAGING PERFORMED BY

Jack Reese

## HOSPITAL NAME

Willow Run Veterinary  
Clinic

## REFERRING VET

Dr. Pendergast

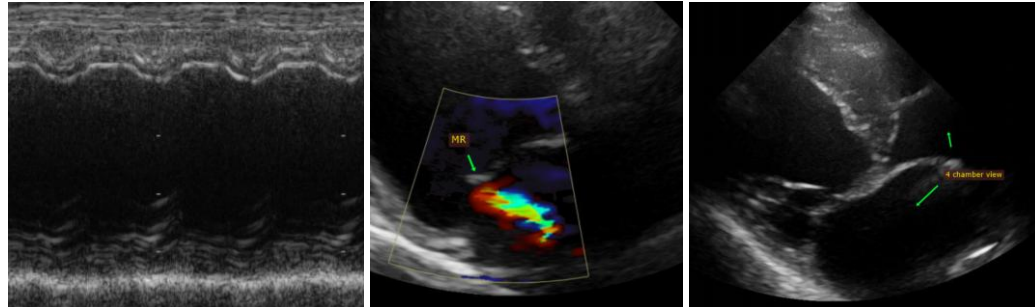
## INVOICE

47640

## DATE

4/22/26

## IMAGES



The information and recommendations provided are based on the images presented by the referring veterinarian. No evaluation can be communicated regarding pathology that was not visible in the image/video clips provided.

Thank you for this referral. This report was generated using transcription software, and minor dictation errors may be present. If the clinical or image interpretation does not parallel your findings or if I can be of any further assistance, please contact me.

**Maggie Machen Lamy, DVM**

**Diplomate of the American College of Veterinary Internal Medicine (Cardiology)**

info@sonopath.com